



ASNR
American Society of
Neuroradiology



ASITN
American Society of
Interventional & Therapeutic
Neuroradiology

WHAT IS AN ARTERIOVENOUS MALFORMATION (AVM)?

*From the Cerebrovascular Imaging and
Intervention Committee of the American
Heart Association Cardiovascular Council*

Randall T. Higashida, M.D., Chair



**American Stroke
Association**SM

A Division of American
Heart Association



THE NEURORADIOLOGY EDUCATION
AND RESEARCH FOUNDATION



This pamphlet is made possible by:
American Society of Neuroradiology
American Society of Interventional
and Therapeutic Neuroradiology
American Stroke Association
A Division of American Heart Association
The Neuroradiology Education
and Research Foundation



FOR FURTHER INFORMATION CONTACT:
AMERICAN SOCIETY OF NEURORADIOLOGY
2210 MIDWEST ROAD, SUITE 207
OAK BROOK, IL 60523
PHONE: (630) 574-0220 FAX: (630) 574-0661
EMAIL: WWW.ASNR.ORG



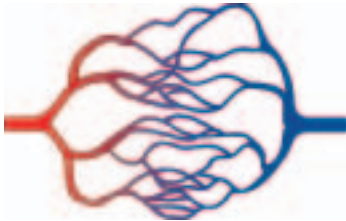
What Is an Arteriovenous Malformation (AVM)?

From the Cerebrovascular Imaging and Intervention Committee of the American Heart Association Cardiovascular Council

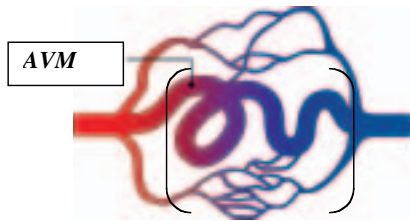
Randall T. Higashida, M.D., Chair

What is a brain AVM?

Normally, **arteries** carry blood containing oxygen from the heart to the brain, and **veins** carry blood with less oxygen away from the brain and back to the heart. When an **arteriovenous malformation (AVM)** occurs, a tangle of blood vessels in the brain or on its surface bypasses normal brain tissue and directly diverts blood from the arteries to the veins.



Normal Blood Vessels



Abnormal Connection of Blood Vessels

How common are brain AVMs?

Brain AVMs occur in less than one percent of the general population. It is estimated that about one in 200–500 people may have an AVM. AVMs are more common in males than females.

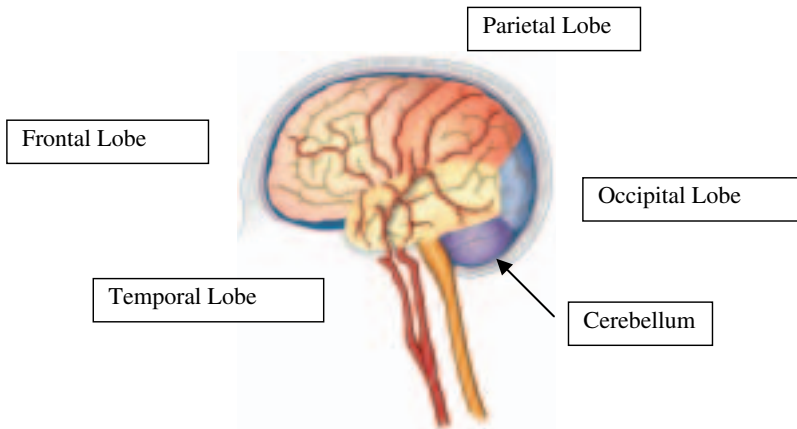
Why do brain AVMs occur?

We do not know why AVMs occur. Brain AVMs are usually congenital, meaning someone is born with one. However, they usually are not hereditary. People probably do not inherit an AVM from their parents, and they probably will not pass an AVM on to their children.

Where do brain AVMs occur?

Brain AVMs can occur anywhere within the brain or on the covering of the brain. This includes the four major lobes of the front part of the brain (frontal, parietal, temporal,

occipital), the back part of the brain (cerebellum), the brainstem, or the ventricles (deep spaces within the brain that produce the cerebrospinal fluid).



Do brain AVMs change or grow?

Most AVMs do not grow or significantly change although the vessels involved may dilate. There are some reported cases of AVMs shrinking or enlarging, but this may be due to clots in parts of an AVM causing it to shrink, or to redirecting adjacent blood vessels toward an AVM.

What are the symptoms of a brain AVM?

Symptoms may vary with location

- More than 50 percent of patients with an AVM complain of headaches.
- 45–60 percent of patients with an AVM have seizures.
- Patients may have localized pain in the head due to increased blood flow around an AVM.
- Difficulty with movement, speech and vision may occur.

What causes brain AVMs to bleed?

A brain AVM contains abnormal and, therefore, “weakened” blood vessels that direct blood away from normal brain tissue. These abnormal and weak blood vessels dilate over time and may eventually burst from the high pressure of blood flow from the arteries causing bleeding into the brain.

What are the chances of a brain AVM bleeding?

There is a 1–3 percent chance per year of a brain AVM bleeding. Over a 15-year period, there is a 25 percent total chance of an AVM bleeding into the brain, causing brain damage and stroke.

Does one bleed increase the chance of a second bleed?

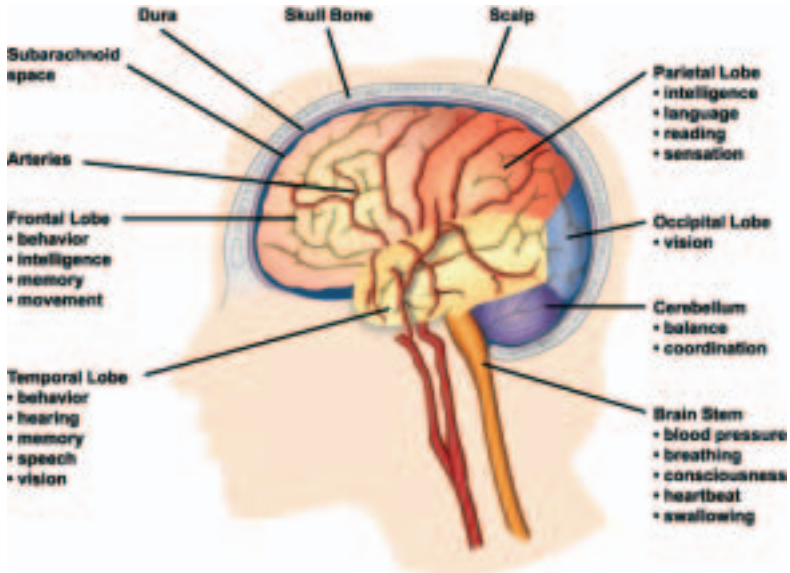
With one bleed, the chance of a second bleed is 25 percent over the next four years, or 6 percent per year. If there are two or more bleeds, the chance of more bleeds is even higher, increasing to 25 percent per year. Individuals with an AVM are at a slightly higher risk of bleeding between the ages of 11 and 35.

What can happen if a brain AVM causes a bleed?

There is a 10–15 percent risk of death related to each bleed and a 20–30 percent chance of permanent brain damage. Each time blood leaks into the brain, normal brain tissue is damaged. This results in loss of normal function, which may be temporary or permanent. Some possible symptoms include arm or leg weakness/paralysis, or difficulty with speech, vision or memory. The amount of brain damage depends upon how much blood has leaked from the AVM.

What functions does an AVM affect?

If an AVM bleeds, it can affect one or more normal body functions, depending on the location and extent of the brain injury. Different locations in the brain control different functions:



- Frontal lobe controls personality.
- Parietal lobe controls movement of the arms and legs.
- Temporal lobe controls speech, memory and understanding.
- Occipital lobe controls vision.
- The cerebellum controls walking and coordination.
- Ventricles control the secretion of cerebrospinal fluid.
- The brainstem controls the pathways from all of the above functions to the rest of the body.

Are there different types of brain AVMs?

Although all blood vessel malformations involving the brain and its surrounding structures are commonly referred to as AVMs, there are actually several types:

- **True Arteriovenous malformation (AVM).** This is the most common brain vascular malformation and consists of a tangle of abnormal vessels connecting arteries and veins with no normal intervening brain tissue.
- **Occult or cryptic AVM or cavernous malformations.** This is a vascular malformation in the brain that does not actively divert large amounts of blood. It may bleed and often produce seizures.
- **Venous malformation.** This is an abnormality only of the veins. The veins are either enlarged or appear in abnormal locations within the brain.
- **Hemangioma.** These are abnormal blood vessel structures usually found at the surface of the brain and on the skin or facial structures. These represent large and abnormal pockets of blood within normal tissue planes of the body.
- **Dural fistula.** The covering of the brain is called the “dura mater.” When there is an abnormal connection between blood vessels that involve only this covering, it is called a dural fistula. Dural fistulas can occur in any part of the brain covering.

There are three kinds of dural fistulas.

- **Dural carotid cavernous sinus fistula.** These occur behind the eye and usually cause symptoms due to diverting too much blood toward the eye. Patients have eye swelling, decreased vision, redness and congestion of the eye. They often can hear a “swishing” noise.
- **Transverse-Sigmoid sinus dural fistula.** These occur behind the ear. Patients usually complain of hearing a continuous noise that occurs with each heartbeat (bruit), local pain behind the ear, headaches and neck pain.

- **Sagittal sinus and scalp dural fistula.** These occur toward the top of the head. Patients complain of noise (bruit), headaches and pain near the top of the head; they may have prominent blood vessels on the scalp and above the ear.

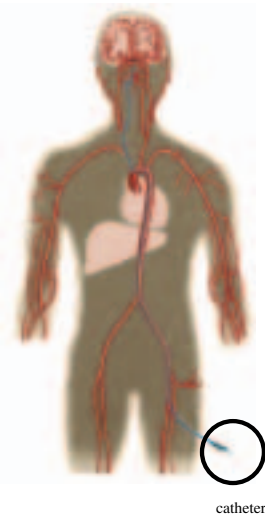What is the best treatment for a dural fistula?

The best treatment is usually endovascular surgical blocking of the abnormal connections that have caused the fistula. This involves guiding small tubes (catheters) inside the blood vessel and blocking off the abnormal connections with X-ray guidance. Depending upon the location and size, many of these can be treated and cured by these endovascular, less invasive techniques.

How are AVMs diagnosed?

Most AVMs are detected on either a computed tomography (CT) brain scan or with a magnetic resonance imaging (MRI) brain scan. These tests are very good at detecting brain AVMs. They also provide information about the location and size of the AVM and whether it may have bled.

A doctor may also perform a cerebral angiogram. This test involves inserting a catheter (small tube) through an artery in the leg and guiding it into each of the vessels in the neck going to the brain, injecting contrast (dye) and taking pictures of all the blood vessels in the brain. For any type of treatment involving an AVM, an angiogram may be needed to better identify the type of AVM.



Cerebral angiogram

What factors influence whether an AVM should be treated?

In general, an AVM may be considered for treatment if it has bled, if it is in an area of the brain that can be easily treated and if it is not too large.

What is the best treatment for an AVM?

This depends upon what type it is, the symptoms it may be causing and its location and size.

What different types of treatment are available?

- **Medical Therapy.** If there are no symptoms or almost none, or if an AVM is in an area of the brain that cannot be easily treated, conservative medical management may be indicated. If possible, a person with an AVM should avoid

any activities that may excessively elevate blood pressure, such as heavy lifting or straining, and they should avoid blood thinners like warfarin. A person with AVM should have regular checkups with a neurologist.

- **Surgery.** If an AVM has bled and/or is in an area that can be easily operated upon, then surgical removal may be recommended. The patient is put to sleep with anesthesia, a portion of the skull is removed, and the AVM is surgically removed. When the AVM is completely taken out, the possibility of any further bleeding should be eliminated.
- **Stereotactic radiosurgery.** An AVM that is not too large, but is in an area that is difficult to reach by regular surgery, may be treated by performing stereotactic radiosurgery. In this procedure a cerebral angiogram is done to localize the AVM. Focused-beam high energy sources are then concentrated on the brain AVM to produce direct damage to the vessels that will cause a scar and allow the AVM to “clot off.”
- **Interventional neuroradiology/endovascular neurosurgery.** It may be possible to treat part or all of the AVM by placing a small tube (catheter) inside the blood vessels that supply the AVM and blocking off the abnormal blood vessels with a variety of different materials. These include liquid tissue adhesives (glues), micro-coils, particles and other materials used to stop blood flowing to the AVM.

The best course of treatment depends upon what type of symptoms the patient is having, what type of AVM is present and the AVM’s size and location.

What doctors specialize in treating brain AVMs?

- **Vascular neurosurgeons** specialize in surgically removing brain AVMs.
- **Radiation therapists/neurosurgeons** specialize in the stereotactic radiosurgery treatment of brain AVMs.
- **Interventional neuroradiologists/endovascular neurosurgeons** specialize in the endovascular therapy of brain AVMs.
- **Stroke neurologists** specialize in the medical management of brain AVMs.
- **Neuroradiologists** specialize in the diagnosis and imaging of the head, neck, brain and spinal cord. They perform and interpret the CT, MRI, and cerebral angiograms necessary for evaluation, management, and treatment.

Each of these specialists has had advanced training and is highly skilled at treating complex brain vascular malformations.

About strokes and cerebrovascular diseases

Stroke and cerebrovascular diseases are the third-leading cause of death and a leading cause of major disability in the United States. More than 700,000 new and recurrent strokes occur each year, resulting in over 167,000 deaths and more than 250,000 permanent disabilities. About 4.7 million stroke survivors are alive today.

Ischemic strokes occur when the normal blood flow to the brain is blocked. They account for the majority of strokes. Treatment is available but must be started as soon as possible to give the best chance for recovery.

Hemorrhagic strokes are caused by bleeding into the brain, resulting in either death or major disability. Many of these strokes occur when a cerebral aneurysm or brain AVM ruptures.

For more information, contact the American Stroke Association, a division of the American Heart Association, at 1-888-4-STROKE (1-888-478-7653) or visit StrokeAssociation.org.

Funded through an educational grant provided by Boston Scientific Corporation



2003, American Society of Neuroradiology